

# First-opinion approach to the dachshund with intervertebral disc herniation

Marianne Dorn



**Marianne Dorn** has worked continuously in small animal practice since qualifying from the Royal (Dick) School of Veterinary Studies, Edinburgh, in 1996. In 2014, she gained a PGCert in small animal rehabilitation through Nottingham veterinary school. For the past four years, she has worked as The Rehab Vet, offering a mobile canine and feline physiotherapy and rehabilitation service in Hertfordshire, while also continuing a part-time role as a small animal veterinary surgeon.

**Intervertebral disc herniation (IVDH) is by far the most likely diagnosis for dachshunds presenting with no history of trauma and with both pain and pelvic limb paresis. A presumptive diagnosis of IVDH can usually be reached based on history and clinical examination, although mild cases can be challenging to differentiate from those with non-spinal causes of pain. This article offers a practical approach to assessing and managing the painful dachshund in first-opinion practice. It covers clinical decision-making and the principles of non-surgical treatment, emphasising the need for good monitoring and follow-up. Recovery typically takes weeks to months; full recovery is not guaranteed, and recurrence is possible, so regardless of whether spinal surgery is performed, good communication between practitioner and owner is essential.**

AMONG all breeds of dog, dachshunds have the highest risk of intervertebral disc herniation (IVDH), with around 15 per cent of standard and 20 per cent of miniature dachshunds presenting with at least one episode of this condition at some stage in their lives (Bergknut and others 2012). Discs in the T11 to L3 region are most often affected (Ito and others 2005, Aikawa and others 2012), resulting in a clinical picture that can vary from a painful dog with no neurological deficits to, in the worst-affected cases, a dog with pelvic limb paralysis and urinary and faecal incontinence. Other presentations are possible depending on the level of the spine affected.

IVDH is unusual in dogs under two years old, but is commonly seen in both male and female dachshunds of three years old and over, with incidence peaking at four to six years of age. There is generally no history of trauma.

Mildly affected dogs may be brought in with vague signs of discomfort – for example, the owner might describe their dog as ‘not quite right in himself’. There are anecdotal reports of such dogs progressing rapidly to collapse following vigorous activity on returning home from the veterinary clinic, so it is important that the possibility of IVDH is considered early on, and that owners are given appropriate home care guidelines and follow-up.

## Terminology

**Intervertebral disc herniation (IVDH)** is displacement of an intervertebral disc due either to acute disc extrusion or to more chronic disc protrusion or bulge.

In chondrodystrophic breeds such as the dachshund, intervertebral discs undergo chondroid metaplasia before the dog reaches two years of age (Hansen 1952). This degenerative process involves a hardening of the central gelatinous nucleus pulposus (NP) so that it can no longer fulfil its role as a hydraulic cushion. The resulting changes in mechanical loading lead to progressive weakening and predispose to rupture of the annulus fibrosus (AF). Eventual rupture of the AF is associated with Hansen

type 1 herniation, an acute or peracute extrusion of the NP into the vertebral canal. Disc extrusion can result in concussion, contusion, compression and, occasionally, laceration of the spinal cord, along with local haemorrhage and ischaemia. Following disc extrusion, vascular changes initiate secondary spinal cord damage, a complex chain of inflammatory pathways leading to progressive loss of neurons, oligodendrocytes and axons (Olby 2010).

Although more commonly associated with non-chondrodystrophic breeds, the more chronic presentations of disc protrusion and bulge may also occur in dachshunds (Hansen 1952).

**Intervertebral disc disease (IVDD)** is an umbrella term encompassing disc degeneration and the various clinical presentations resulting from disc herniation.

## Diagnostic approach

At first presentation, the diagnostic goals include:

- Ruling IVDH in or out as a likely diagnosis; and
- If IVDH is present, ascertaining the clinical severity of the condition, and hence the prognosis.

A presumptive diagnosis of IVDH is generally based on history and clinical examination (Fig 1). If definitive diagnosis is required (eg, before decompressive surgery) then magnetic resonance imaging (MRI) or other advanced imaging would be needed. Spinal radiography is unlikely to be diagnostic, and is rarely useful in these cases unless signs have resulted from severe trauma.

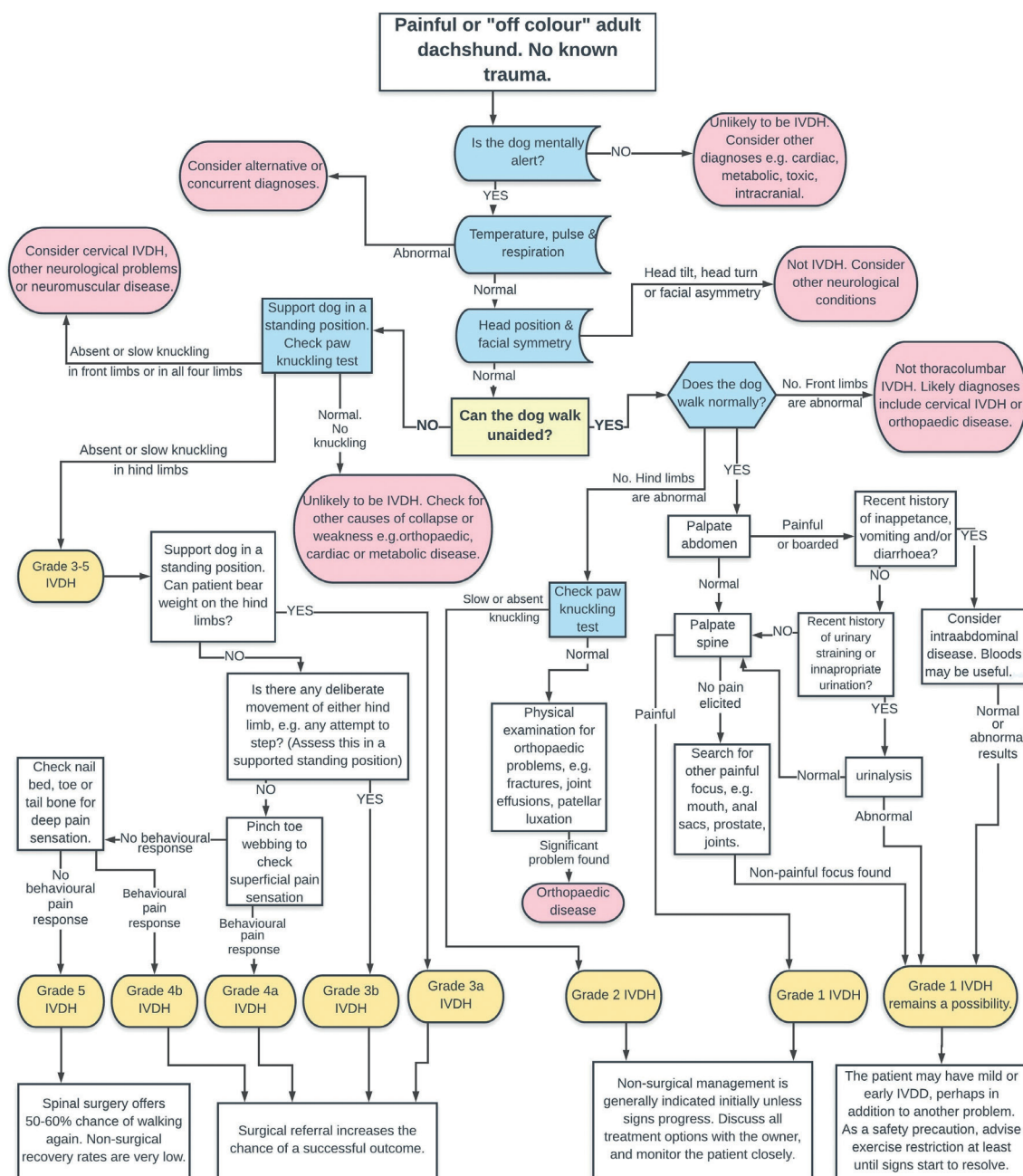
## History

General history should include any recent changes in appetite, gastrointestinal signs and urinary tract signs, for example:

- When did the dog last urinate?
- Has the dog urinated unexpectedly indoors?

Another important question to ask is:

- Is there any history of falls or other trauma?



**Table 1: Clinical presentations of dogs affected by intervertebral disc herniation (IVDH)**

Region of spine affected	Gait	Postures	Other clinical findings	Neurological examination findings
C1–C5	Mild cases walk normally or appear stiff through the neck when moving More severely affected cases are tetraparetic or tetraplegic	Severe cases are collapsed in sternal or lateral recumbency FLs rigid and extended The patient may be unable to lift head and neck	Tender on neck palpation, reluctant to turn head +/- signs of generalised pain +/- UMN bladder (high tone, difficult to express) +/- Altered respiratory pattern +/- Horner's syndrome	Normal to increased withdrawal reflex FLs and HLs Patellar reflex normal to increased Delayed proprioceptive knuckling test in FLs and HLs
C6–T2 (a rare location for IVDH in small-breed dogs)	Mild cases walk normally or appear stiff when moving More severely affected cases are tetraparetic or tetraplegic	Severe cases are collapsed in sternal or lateral recumbency	Signs of localised or generalised pain Horner's syndrome may occur if T1–T3 nerve roots affected +/- tachypnoea with reduced chest excursions and paradoxical respiration +/- UMN bladder	Reduced withdrawal reflex in FLs Delayed proprioceptive knuckling test in FLs and HLs Patellar and HL withdrawal reflexes normal or increased
T3–L3 (most common presentation for dachshunds)	Mild cases walk normally or appear stiff when moving Signs of HL paresis and ataxia include a 'staggering' gait with paws placed medially or laterally; claws may be scuffed as paws lift; knuckling, dragging or crossing-over of HL paws may occur Severely affected dogs are unable to bear any weight on the HLs. They move by dragging themselves forward with the FLs	If the dog is able to stand, the spine may be kyphotic (Fig 2) May present as recumbent, or may be observed sitting with kyphotic spine, FLs placed caudally, and HLs extended cranially or caudally Sometimes see Schiff-Sherrington posture with rigid extended FLs in lateral recumbency	Abdominal wall may be tense +/- UMN bladder (high tone, difficult to express)	FLs normal (strength, proprioceptive reflexes and spinal reflexes) HLs slow or absent proprioceptive knuckling reflex Patellar and HL withdrawal reflexes normal or increased (these reflexes may be temporarily reduced due to spinal shock) Abnormal trunci muscle reflex (panniculus) cut-off can help to localise the lesion within this section of the cord
L4–S3	HL ataxia, paresis or paralysis (as for T3–L3)	May present as recumbent, or may be observed sitting with lordotic spine, FLs placed caudally, and HLs extended cranially or caudally	Anal tone may be reduced if S1–S3 involved +/- UMN or LMN bladder Reduced tone in HL muscles	Patellar reflex may be reduced if L4–L6 involved Withdrawal reflex in HLs may be reduced if L6–S1 affected HL muscle tone and strength on hopping may be reduced

FL Front limb (thoracic limb), HL Hind limb (pelvic limb), LMN Lower motor neuron, UMN Upper motor neuron



**Fig 2: Characteristic kyphotic standing posture of the ambulatory dachshund with thoracolumbar intervertebral disc herniation**

A diagnosis of IVDH is further supported by an abnormal proprioceptive paw placement test (Fig 3) and by tenderness on paraspinal pain testing (Fig 4).

Extensive neurological testing is not required for either diagnosis or grading. If performed, cranial nerve tests are expected to be normal. Further neurological tests can help localise the lesion (Table 1).

For dogs presenting with pain plus postural and gait deficits typical of IVDH, differential diagnoses include spinal neoplasia and discospondylitis. Pyrexia, unexplained

recent weight loss or other systemic signs should prompt further investigation (Fig 1). However, in dachshunds, these conditions are seen much less frequently than IVDH.

Distress can alter behaviour, gait, posture and muscle tone, making it difficult or impossible to assess the dog and to localise the source of pain. Anxiety may also worsen the clinical situation by contributing to painful increased muscle tension. Therefore, it is vital to minimise anxiety throughout diagnosis and management (Table 2).

### Clinical grading of IVDH

Prognosis depends on the clinical severity of IVDH. Therefore, assessing clinical grade helps guide decision-making and enables the clinician to monitor for recovery or deterioration (Fig 1, Table 3). Dogs may present acutely at any grade, or may initially present with mild signs which progress over hours to days.

In grading the patient's disease, key questions you should ask are:

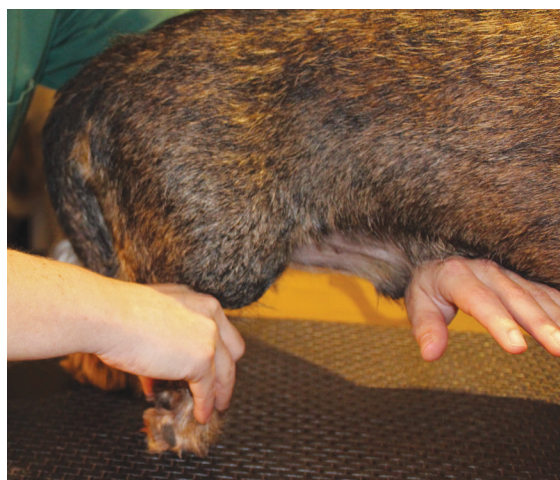- Can the patient walk unaided? Ambulatory dogs are grade 1 or 2. Non-ambulatory dogs are grade 3 to 5.
- Is voluntary movement present in affected limbs? Dogs lacking voluntary movement are grade 4 or 5.
- Is deep pain sensation present? Dogs with no deep pain sensation are grade 5.

### Checking for deep pain sensation

An absence of deep pain sensation indicates a worse



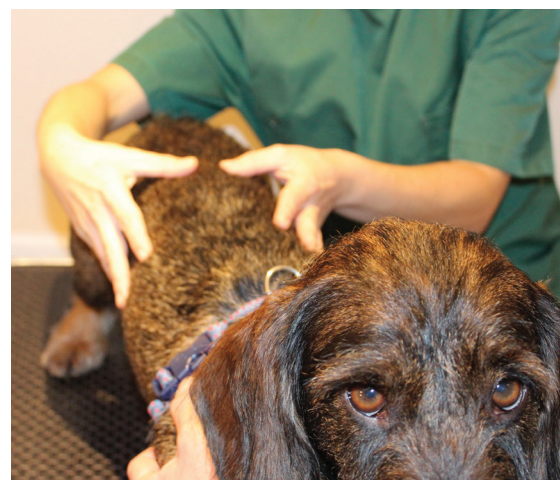**Fig 3:** Performing the proprioceptive knuckling test. Lift the paw and place it on its dorsal surface – a normal dog will briskly replace the paw with pads down; failure to replace a knuckled paw within two seconds indicates poor proprioception. Note the supportive hand placed under the dog's abdomen



prognosis [Ito and others 2005, Aikawa and others 2012]. However, nociception should only be tested in severely affected dogs. If a limb still has conscious movement then deep pain sensation should be present, and pain testing would cause unnecessary distress.

To test superficial pain sensation, pinch a toe webbing firmly. A dog with an intact pain sensation will show a behavioural response by turning its head, vocalising, biting, licking its lips, etc.

Only test deep pain sensation if superficial pain sensa-



**Fig 4:** Gentle pressure is applied to each pair of vertebral transverse processes to test for paraspinal hyperaesthesia. Discomfort may cause the patient to flinch, shift to a 'sit' position, lip-lick, yawn, turn the head or vocalise. For paretic dogs, the clinician may prefer to support under the dog's chest or belly with one hand while pain testing using finger and thumb pads of the other hand

tion appears to be absent. Apply haemostats transversely across a nail bed or toe bone and observe for a behavioural response. If deep pain sensation is absent in the pelvic limbs, then repeat the test on the tail.

Note that pinching a toe may cause reflex flexion (withdrawal) of the limb regardless of whether nociception is present.

### Differentiating mild IVDH from other diseases

Mild IVDH, with pain as the sole presenting sign, presents a diagnostic challenge. There are anecdotal reports of dachshunds with early IVDH deteriorating shortly after being diagnosed as having dental or anal sac disease, cystitis, dermatitis, patellar luxation or gastrointestinal tract disease.

Dogs presenting with vague signs should ideally not be sent away with a presumptive diagnosis of non-spinal disease. A full general examination helps to assess possible comorbidities or alternative diagnoses, with urinalysis and serum biochemistry being useful in select cases. Pancreatitis is an important differential diagnosis as, like grade 1 IVDH, it may present with pain and reduced appetite but no vomiting or diarrhoea. However, cPLI (canine pancreatic lipase immunoreactivity) concentration has been shown to be raised in dogs with IVDH [Schueler and others 2018], and is therefore not a useful test for differentiating between IVDH and pancreatitis.

If disc-related pain has not been ruled out, explain this to the owner and have them restrict the dog to short lead walks with no running or jumping at least until signs have started to resolve. Avoid any non-essential general anaesthesia (eg, for dental work) in these cases. Reduced muscle tone and anaesthetic-associated hypoxaemia may put the dog at risk of an acute worsening of a low-grade disc extrusion [Rose 2017].

### Decision-making

Good communication with owners is essential. Clinical signs may progress or recur; therefore, even if not required immediately, spinal surgery may become the preferred option at a later stage.

**Table 2: Minimising canine anxiety and pain during clinical examination**

Measure	Notes
Non-slip surfaces	Perform gait assessment on non-slip flooring Perform physical examination on a non-slip surface (eg, rubber-backed matting)
Floor versus table	Some dogs lose confidence once placed on a raised table. Consider examining these dogs on the floor
Comfortable substrate	The recumbent dog should be examined on a comfortable surface (eg, a piece of Vetbed). Place rubber matting underneath this to prevent slipping
Position yourself carefully	Position yourself so as to face in the same direction as the patient as far as is possible during hands-on clinical examination (Fig 4). Meanwhile, the dog's owner is generally best positioned sitting or standing facing their dog
Initial hands-off examination	Much information can be gained from observing the patient's gait and postures. Watch the patient as it enters the consulting room and while taking a history, and note as much information as possible hands-off at this early stage
Restraint	Avoid neck or collar restraint during examination if possible. Holding onto the dog's chest harness, or placing hands around the rib cage, offers support closer to the dog's centre of gravity and will help the dog to stay calm
Minimise pain testing	Introduce your touch to the dog in a non-painful and non-threatening manner (eg, start by stroking over the shoulder region). Keep any pain testing to a minimum and leave this to a later stage of the examination. Once paraspinal pain has been identified on examination, avoid repeatedly pressing over the spine to confirm or monitor this. Anxiety related to pain on handling is not conducive to recovery
Respond to calming signals	Observe the patient for calming signals such as repeated lip-licking and/or yawning. These behaviours indicate either that the dog is anxious or, if you are touching a tender region, that you are causing the dog discomfort
Offer manual support	Take care to avoid tipping the dog off balance (eg, when assessing each limb). If attempting any three-legged assessment in the standing dog then place a supportive hand under the dog's chest or abdomen (Fig 3)
Encourage patient cooperation	Painful dogs may be able to walk but reluctant to do so. Do not attempt to drag the patient. Instead, encourage cooperation by walking the dog towards its owner, towards a food reward, or towards an opened exit door

**Table 3: Clinical grading scale for thoracolumbar intervertebral disc disease**

Grade	Description	What percentage of dogs get better without surgery?*	What percentage of dogs get better with surgery?*
1	Painful, <sup>†</sup> but able to walk normally or almost normally	70 to 100 per cent <sup>1-3</sup>	
2	Able to walk; the walk is wobbly and/or ataxic ('drunken sailor'-type walking)	55 to 100 per cent <sup>1-3</sup>	About 95 per cent <sup>4</sup>
3a	Unable to walk or stand unassisted Can bear weight on affected legs if the body is supported		93 per cent (90 to 96 per cent) <sup>5</sup>
3b	Unable to walk or stand unassisted Cannot bear weight on affected legs, even if the body is supported	79 per cent (21 to 98 per cent) <sup>5</sup>	Mean time to ambulation 10 days <sup>5</sup>
4a	Cannot make any deliberate movements with the affected legs		93 per cent (88 to 96 per cent) <sup>5</sup>
4b	Cannot make any deliberate movements with the affected legs plus No superficial pain sensation in toes of affected legs	62 per cent (48 to 74 per cent) <sup>5</sup>	Mean time to ambulation 15 days <sup>5</sup>
5	Cannot make any deliberate movements with the affected legs plus No deep pain sensation in toes of affected legs	10 per cent (3 to 29 per cent) <sup>5</sup>	61 per cent (53 to 68 per cent) <sup>5</sup> Mean time to ambulation 38 days, <sup>5</sup> although recovery can take nine months or more

\* Where available, 95 per cent confidence intervals are shown in brackets

† Dogs of all grades (1 to 5) tend to be painful, especially around the affected area of their spine

References: 1 Levine and others 2007; 2 Davies and Sharp 1983; 3 Hayashi and others 2007; 4 Aikawa and others 2012; 5 Langerhuus and Miles 2017

Whether or not surgery is performed, owners should be prepared for a recovery period involving careful activity restriction and time-consuming home care. This may present practical problems; for example, if the owner works long hours away from home or is physically unable to lift their own dog.

### What is a good outcome?

The ideal aim is to return each IVDH patient to a comfortable lifestyle, mobile enough to resume regular walks and to negotiate the home environment, and to regain urinary and faecal control, as persistent incontinence is unacceptable for many owners. Good long-term pain control is essential. Being unable to walk is an unacceptable outcome for some, but not all, dogs and owners. Perhaps sur-

prisingly, many dachshunds do well long term in a 'cart' (Fig 5), and some owners are content with this outcome.

### Choosing whether to refer for surgical decompression

MRI or other advanced imaging is required for the definitive diagnosis of IVDH, and some owners are keen to pursue this even if surgery is not essential. Therefore, neurological referral should be offered whenever IVDH is suspected on clinical examination.

If the dog is non-ambulatory or if signs are progressive, then decompressive surgery offers the best chance of a good outcome (Langerhuus and Miles 2017). However, non-surgical management is generally a sensible option for dogs that are able to walk unaided, so long as pain is well controlled. Non-surgical management can also be considered for non-ambulatory dogs if financial or other considerations preclude surgery, although full recovery is less certain (see Table 3). Non-surgical management is unlikely to be successful if deep pain sensation is absent, although the results of clinical studies vary (Davies and Sharp 1983, Hayashi and others 2007, Levine and others 2007, Joachim and others 2010).

It may be appropriate to allow the owner at least 24 hours to make a decision before proceeding with a surgical referral. Owners need to consider the financial costs of surgery and of any expected aftercare. The non-ambulatory dog with intact deep pain sensation is not expected to walk immediately following successful surgery, and is likely to require sling support for one to two weeks postoperatively, with occasional cases taking two months or longer to become ambulatory (Davis and Brown 2002, Ferreira and others 2002, Ito and others 2005, Aikawa and others 2012). The patient may initially have poor control of its bladder and bowels on returning home, although this usually resolves. A good outcome is not guaranteed fol-

**Fig 5: A non-ambulatory dachshund using a cart**







**Fig 6:** Outdoor time during recovery from decompressive thoracolumbar spinal surgery. The hindquarter sling supports the rear end. The lead and chest harness prevent the patient from rushing forward, giving it a chance to stand and step with its paretic hindlimbs

Following spinal surgery, and clinical signs may recur due to subsequent extrusion of another disc(s).

Pending surgery, supportive care is essential, including good analgesia, and exuberant activity must be avoided. Clinical studies show that delaying surgery by up to six days (Davis and Brown 2002) or longer (Ito and others 2005) in grade 3 to 4 dogs does not adversely affect long-term outcome, and that outcome in grade 5 dogs is unaffected if surgery is performed more than 48 hours after loss of nociception (Scott and McKee 1999, Ito and others 2005, Jeffery and others 2016). Nevertheless, surgery must not be delayed unduly if signs are progressing.

If deep pain sensation is absent, then surgical outcome is uncertain, with only 50 to 60 per cent of dogs regaining ambulation (Scott and McKee 1999, Ito and others 2005,



**Fig 7:** 'Supported standing' is a functional exercise that improves proprioception and strength and is therefore good preparation for learning to walk. For this patient at three weeks after spinal surgery, supported standing was combined with lifting each front paw. This not only added to the challenge but was a trick that she'd always enjoyed

Aikawa and others 2012, Jeffery and others 2016). Even if surgery is performed, dogs lacking deep pain sensation have about a one in six chance of irreversible deterioration due to progressive myelomalacia during the first week postoperatively. Following successful surgery in grade 5 dogs, owners should expect a period of weeks to months during which their dog will be unable to walk unaided. Additionally, the dog may be left with an abnormal gait, and some degree of urinary and faecal incontinence, which may be permanent or take months to resolve.

## Non-surgical management

Non-surgical management of IVDH involves:

- Pain management;
- Activity modification –
  - Promote motor recovery by practising coordinated activities
  - Avoid exuberant activities, including running, jumping and the use of stairs
  - Minimise compensatory gait patterns
- Nursing care;
- Bladder and bowel management;
- Respiratory management (mainly for cervical IVDH);
- For acutely presenting cases, maintenance of systemic blood pressure and oxygenation.

Ambulatory dogs (grade 1 to 2) are relatively straightforward to manage at home, requiring analgesia and activity modification. Care of the non-ambulatory dachshund (grade 3 to 5) is more challenging and can be overwhelming for owners, although many are willing to learn the necessary skills for home care, including sling walking (Fig 6), positioning, safety considerations and, if needed, bladder expression.

Admission is recommended for at least the first 24 hours after the diagnosis of IVDH in some cases to enable good nursing, analgesia, close monitoring (Table 4), bladder management and maintenance of blood pressure and oxygenation. Admission also allows the owner to prepare their home for the care of an ataxic or recumbent dog.

## Pain management

Canine IVDH causes severe neuropathic and inflammatory pain requiring multimodal analgesia; for example, gabapentin alongside an NSAID. Further options for inpatients include ketamine or lidocaine constant rate infusions and opioids. Paracetamol may also be useful as part of multimodal analgesia, especially if NSAIDs are contraindicated. Gentle handling and attention to environmental comfort are, of course, essential as part of the pain management protocol.

Steroids are no longer considered to be beneficial and may be contraindicated in the management of acute and chronic IVDH (Hurlbert 2000, Levine and others 2007, Olby and others 2016).

## Activity modification

Practising coordinated activities promotes functional recovery and is best started as soon after injury as possible (Fouad and Tetzlaff 2012). During the first week of recovery, physiotherapy exercises appropriate for most dogs include:

- Maintaining a standing or sitting position with as much manual support as necessary;
- Rising to a standing position from a sitting or lying position with assistance; and
- Slow walking (with support from hands or a sling if required).

Table 4: Inpatient monitoring of dachshunds with intervertebral disc herniation (IVDH)

Assessment	Action	Notes
Pain	Reassess for signs of pain at least every two to four hours <ul style="list-style-type: none"> <li>Assess the dog's posture and demeanour from outside the cage</li> <li>Approach the cage, call the dog by name, and assess its reaction</li> <li>Finally, stroke the dog gently and assess its response</li> </ul>	Adjust analgesics to effect
Urination	Record any voluntary urination Record any urine overflow Check bladder size at least every eight hours	Place a urinary catheter or manually express the bladder if required
Skin	Check bony prominences every four to eight hours for sores	Clean and dry suspicious areas of skin meticulously, supply extra bedding, +/- apply topical barrier cream, antimicrobial or granulation-stimulating agent if required
Clinical grade	At least every eight to 12 hours, reassess clinical grade (see Table 3) <ul style="list-style-type: none"> <li>Assess ability to bear weight in a standing position (with manual support if required)</li> <li>In severely affected dogs, check for presence or absence of voluntary movement in affected limbs</li> <li>In ambulatory dogs, assess the degree of ataxia. Video footage is useful in recording trends of improvement or deterioration</li> </ul>	Keep owner informed Deterioration may be an indication for urgent surgical referral
Systemic blood pressure	Doppler or oscillometric blood pressure measurement	Treat hypotension with intravenous fluids to effect
Oxygenation	Pulse oximetry and/or arterial blood gas monitoring	Supplement oxygen if required
Respiration	Auscultate lung fields to check for adventitious sounds, and monitor respiratory rate and effort	Chest coupage and oxygen supplementation may be required

For consistency, pain scales can be used (eg, the short form of the Glasgow Composite Measure Pain Scale [Reid and others 2007])

Avoid prophylactic antimicrobial therapy of catheterised dogs. Urinary tract infections are common in dogs with IVDH whether or not a catheter has been used. Monitor as required

To help prevent skin sores, provide supportive soft bedding, keep skin clean and dry, and turn recumbent patients at least every four hours

If loss of nociception will prompt euthanasia or other change of treatment plan, then reassess superficial (and if needed, deep) digital pain sensation up to every 24 to 48 hours. Avoid unnecessarily noxious or frequent testing as this is not conducive to recovery

Maintaining systemic blood pressure will improve outcome [Olby 2010]

Maintaining oxygenation will improve outcome [Olby 2010]

Dogs with cervical IVDH may have an inefficient respiratory pattern, making them prone to atelectasis, secretion retention, hypoxaemia and pneumonia

## Box 2: A 'safe area' for recovery

Owners should set up a 'safe area' for their recovering dog. The goal is to prevent access to stairs and other hazards, and to prevent the dog from jumping on and off the sofa. An indoor pen (Fig a) is ideal for most dachshunds, although escapees may need a large, closed-top cage. Alternatively, the safe area could be a room with non-slip flooring and no access to furniture or steps. Whenever outside this safe area, the dog must be either carried or on a lead. Avoid confining the dog in too small a cage, as this forces the patient to turn too tightly and is likely to cause distress [Dorn 2017].

For the safe area to be accepted by the dog, it should be introduced gradually if possible. Set it up comfortably with bedding, food and water before first showing it to the patient. Food-dispensing toys can help to alleviate boredom. Further detailed home care advice for owners is available at <http://therehabvet.com/recovering-dogs-advice-for-owners/>



Fig a: A miniature dachshund in a recovery pen

Exercises should only be attempted on a non-slip footing, ideally at floor level and with a harness in place for safe restraint. Sessions must be kept short, with intensity adjusted as necessary to avoid fatigue. Exercises may be progressed (Fig 7) under professional guidance depending on reassessment of proprioception and strength. Time and care are required to teach exercises to owners if they are to safely assist their dog with these at home.

Running, jumping, rough play, ball play, rushing over slick surfaces and use of stairs must be avoided because large and unpredictable biomechanical forces may predispose to further disc extrusion. At home, this is achieved by setting the dog up in a 'safe area' (Box 2), by carrying the dog over steps and other obstacles, and by careful lead restraint. Regardless of whether surgery is performed, high speed turns and jumping should be avoided for at least six weeks.

Outdoor time should initially be restricted to five minutes (less in some cases), three to six times daily, which would be mainly for toileting purposes. A harness and fixed-length lead offer the safest restraint. Non-ambulatory dachshunds should be carried outdoors and placed on the ground with manual or sling support. Handlers should not support the dog's weight by its tail as this can cause further pain and injury.

Dogs that learn to move by dragging their pelvic limbs soon find this a difficult habit to break, making it increas-



ingly difficult to learn quadrupedal walking. Setting the animal up in a safe area with non-slip flooring and using a hindquarter sling for non-ambulatory patients will help avoid this happening.

### Bladder management

Dogs severely affected by IVDH may be unable to urinate voluntarily. Consider placing an indwelling urethral Foley catheter if manual expression is difficult. Drain urine two to four times daily from the collection system and remove the catheter once it is expected that manual bladder expression will be possible.

Urinary and faecal control has an important behavioural component. Failure to provide outdoor toilet breaks may cause discomfort, distress (Wagner and others 2014) and a failure of house training. Dogs should be offered behavioural stimuli for appropriate urination and defecation: from the first day of recovery, the dog should be taken to an appropriate patch of outdoor ground to urinate and defecate regularly. If needed, the handler should help the dog to maintain a standing position for toileting by means of manual support and/or a hindquarter sling. To provide behavioural stimulus for retraining voluntary urination, bladder expression, if required, should ideally be performed outdoors with the dog supported in a standing position.

### Follow-up

Good follow-up is essential following a presumptive diagnosis of IVDH. A next-day consultation is advisable. Encourage the owner to discuss any problems that they might be experiencing with nursing care and with keeping their dog safely restrained and confined.

Recheck postures, gait, proprioception and weight-bearing ability (assessed in a supported standing position if the dog is weak). Discuss any previous signs of pain noted by the owner. Have these improved or progressed? Also note any discomfort caused by gentle handling.

Ask about appetite and find out whether the dog has urinated and defecated normally. Indoor urination may be due to overflow rather than indicating a return of voluntary urinary control. Palpate the bladder for size and tone. This consultation is a good opportunity, if required, to teach owners how to express their dog's bladder.

The options of referral or admission can be discussed again at this stage. Decompressive surgery may improve outcome if clinical grade has increased (Table 3), especially if the patient has become non-ambulatory.

Admission or very frequent consultations are advisable for the first few days after diagnosis if the dog cannot urinate voluntarily, at least until the owner can manage bladder expression. Further rechecks should be arranged for the stable patient as needed (eg, every seven to 14 days, or sooner if deteriorating) especially to reassess analgesia requirements.

### Conclusion

IVDH is by far the most likely diagnosis for dachshunds presenting with no history of trauma, and with both pain and pelvic limb paresis or paralysis. A presumptive diagnosis can usually be made in first-opinion practice based on history and clinical examination, although mild IVDH can be challenging to differentiate from non-spinal cases of pain. Surgical referral is expected to improve outcome for non-ambulatory dogs with IVDH.

The role of first-opinion vets includes supportive care of acutely affected dogs; monitoring functional status, pain control and bladder function; referring dogs as needed for imaging, surgery and/or physiotherapy; prescribing analgesics; and offering advice on home care.

### References

- AIKAWA, T., FUJITA, H., KANAZONO, S., SHIBATA, M. & YOSHIGAE, Y. (2012) Long-term neurologic outcome of hemilaminectomy and disk fenestration for treatment of dogs with thoracolumbar intervertebral disk herniation: 831 cases (2000–2007). *Journal of the American Veterinary Medical Association* **241**, 1617–1626
- BERGKNUT, N., EGENVALL, A., HAGMAN, R., GUSTÅS, P., HAZEWINKEL, H. A., MEIJ, B. P. & LAGERSTEDT, A. S. (2012) Incidence of intervertebral disk degeneration-related diseases and associated mortality rates in dogs. *Journal of the American Veterinary Medical Association* **240**, 1300–1309
- DAVIES, J. V. & SHARP, N. J. H. (1983) A comparison of conservative treatment and fenestration for thoracolumbar intervertebral disc disease in the dog. *Journal of Small Animal Practice* **24**, 721–729
- DAVIS, G. J. & BROWN, D. C. (2002) Prognostic indicators for time to ambulation after surgical decompression in nonambulatory dogs with acute thoracolumbar disk extrusions: 112 cases. *Veterinary Surgery* **31**, 513–518
- DORN, M. (2017) Crate confinement of dogs following orthopaedic surgery. Part 2: practical recovery area considerations. *Companion Animal* **22**, 604–613
- FERREIRA, A. J. A., CORREIA, J. H. D. & JAGGY, A. (2002) Thoracolumbar disc disease in 71 paraplegic dogs: influence of rate of onset and duration of clinical signs on treatment results. *Journal of Small Animal Practice* **43**, 158–163
- FOUAD, K. & TETZLAFF, W. (2012) Rehabilitative training and plasticity following spinal cord injury. *Experimental Neurology* **235**, 91–99
- HANSEN, H. J. (1952) A pathologic-anatomical study on disc degeneration in dog, with special reference to the so-called enchondrosis intervertebralis. *Acta Orthopaedica Scandinavica Supplementum* **11**, 1–117
- HAYASHI, A. M., MATERA, J. M. & DE CAMPOS FONSECA, A. C. B. (2007) Evaluation of electroacupuncture treatment for thoracolumbar intervertebral disk disease in dogs. *Journal of the American Veterinary Medical Association* **231**, 913–918
- HURLBERT, R. J. (2000) Methylprednisolone for acute spinal cord injury: an inappropriate standard of care. *Journal of Neurosurgery: Spine* **93**, 1–7
- ITO, D., MATSUNAGA, S., JEFFERY, N. D., SASAKI, N., NISHIMURA, R., MOCHIZUKI, M., KASAHARA, M. AND OTHERS (2005) Prognostic value of magnetic resonance imaging in dogs with paraplegia caused by thoracolumbar intervertebral disk extrusion: 77 cases (2000–2003). *Journal of the American Veterinary Medical Association* **227**, 1454–1460
- JEFFERY, N. D., BARKER, A. K., HU, H. Z., ALCOTT, C. J., KRAUS, K. H., SCANLIN, E. M., GRANGER, N. & LEVINE, J. M. (2016) Factors associated with recovery from paraplegia in dogs with loss of pain perception in the pelvic limbs following intervertebral disk herniation. *Journal of the American Veterinary Medical Association* **248**, 386–394
- JOAQUIM, J. G., LUNA, S. P., BRONDANI, J. T., TORELLI, S. R., RAHAL, S. C. & DE PAULA FREITAS, F. (2010) Comparison of decompressive surgery, electroacupuncture, and decompressive surgery followed by electroacupuncture for the treatment of dogs with intervertebral disk disease with long-standing severe neurologic deficits. *Journal of the American Veterinary Medical Association* **236**, 1225–1229
- LANGERHUUS, L. & MILES, J. (2017) Proportion recovery and times to ambulation for non-ambulatory dogs with thoracolumbar disc extrusions treated with hemilaminectomy or conservative treatment: A systematic review and meta-analysis of case-series studies. *Veterinary Journal* **220**, 7–16
- LEVINE, J. M., LEVINE, G. J., JOHNSON, S. I., KERWIN, S. C., HETTLICH, B. F. & FOSGATE, G. T. (2007) Evaluation